

# A Novel Treatment of Auricular Keloid

Khalifa E Sharquie<sup>1</sup>, Thamir A Kubaisi<sup>2</sup>, Raid M. Al-Ani<sup>3</sup>

<sup>1</sup>Department of Dermatology, College of Medicine, University of Baghdad, Center of Dermatology, Medical City Teaching Hospital, Baghdad, Iraq.

<sup>2</sup>Department of Internal Medicine/ Dermatology, College of Medicine, University of Anbar; Ramadi, Anbar, Iraq.

<sup>3</sup>Department of Surgery/Otolaryngology, College of Medicine, University of Anbar, Anbar, Iraq.

## Abstract

**Background:** Auricular keloids are not uncommon skin problem that is observed among young females following ear piercing. They can occur in earlobes as well as in the skin and cartilage higher on the ear. Different types of therapy are available, but are often followed by relapse.

**Objective:** To assess the efficacy and safety of the intralesional injection of combination of steroid and methotrexate, followed by shaving.

**Methods:** This is a prospective, case series included 9 women with 11 auricular keloids. All patients gave a history of ear piercing that was followed by the appearance of keloid. Full data from the participants regarding the demographic and clinical characteristics were described. After intralesional injection of keloid with combination of triamcinolone (20 mg in 0.5ml) and (10 mg in one ml) methotrexate, shaving of the lesion with a scalpel and a simple diathermy needle was performed. Then patients were followed after 3-4 weeks, and the combination injection was also done again. Follow-up was carried on regular basis for one year.

**Results:** Nine females were treated by this new therapeutic regime; their ages ranged from 18 to 33 years, with a mean of 27 years. Seven patients had a single keloid on one side, while two patients had a single lesion on both ears. All patients had complete clearance of keloids without complications, like infection or new keloid formation. No relapses were recorded within a one-year follow-up period.

**Conclusion:** This novel modality shows excellent cosmetic appearance with no recurrence during a one-year follow-up.

**Keyword:** Cosmetic debulking; Ear piercing; Ear keloids; Intralesional injection; Triamcinolone; Methotrexate.

**Received:** April 06, 2026

**Revised:** May XX, 2026

**Accepted:** May XX, 2026

**Published:** May 30, 2026

**Citation:** Sharquie KE, Kubaisi TA, Al-Ani RM. A Novel Treatment of Auricular Keloid. *Pak J Med Surg Aesthet.* 2026;2(1):18-24.

## Introduction

Keloids are an excessive synthesis and deposition of collagen as a result of an atypical healing response. This term is derived from the Greek word cheloides, which refers to a crab's claw.<sup>1</sup> Generally, it involves the shoulders, chest, upper back, earlobes, and arm, after trauma like surgery, body piercing, burns, scalds or follow disease process, like boil, acne, or varicella.<sup>2,3</sup>

Piercing earlobes is a widespread practice as a sign of beauty and decorative earrings, and this might activate the keloid development, resulting in an unwanted, large, globular fibrous mass.<sup>4</sup> The likelihoods of keloids formation following ear piercing are higher after the age of 11 years.<sup>2,4</sup> The differential diagnosis of the keloid lesion including hypertrophic scar, implanted foreign bodies, epidermal cyst, trichoepithelioma, and sarcoidosis.<sup>5,6</sup>

Although there are numerous treatment options for keloids, the recurrence rate is high. These options include intralesional injection, surgical excision, pressure therapy, cryotherapy, silicone gel sheets, or a combination of these methods is recommended, even for recurrent lesions.<sup>2,3</sup> Whenever surgical excision is used to treat auricular keloids, the prognosis is better, and they are less likely to recur than keloids in other locations but still excision and suturing is not advised.<sup>7</sup> The surgery has been the preferred treatment for the keloids of the pinna, which has produced the best outcomes. Dissection is made possible by the use of a keloid fillet flap of the keloid core, allowing the skin to remain loose and impact closure. The combining excision with other postoperative techniques like injection of corticosteroid or interferon therapy results in an even higher reduction in recurrence rates.<sup>2,8</sup>

Recently, it was demonstrated that keloid debulking plus intralesional injection of methotrexate and triamcinolone was an extremely statistically significant and innovative and effective modality of therapy, due to low rate of recurrence with fewer adverse effects.<sup>1</sup> Regarding response to the treatment for abnormal scar, many clinical evaluations depend on the Vancouver Scar Scale (VSS), but occasionally, it is unapplicable. Therefore, we need to modify this score, and include patient satisfaction to the pliability and height of auricular keloid.<sup>9</sup>

Among the previous decades, many proposed trials for ear keloid have been reported, with diverse marks of success and different rates of recurrence.<sup>10-14</sup> Therefore, this study aimed to evaluate the efficacy and safety of the combination of steroid and methotrexate followed by shaving and to repeat the injection again.

**Address or corresponding**

Prof. Khalifa E Sharquie MD, PhD, FRCP(Edin), FRCP (London)  
Department of Dermatology, College of Medicine,  
University of Baghdad, Iraqi and Arab Board of  
Dermatology and Venereology, Center of Dermatology  
and Venereology, Baghdad Teaching Hospital, Medical  
City, Medical Collection Office, P.O. BOX 61080,  
Postal code 12114, Baghdad, Iraq.  
Ph: +9647901468515; Email: ksharquieprof@yahoo.com

**Methods**

This is a prospective, case series, and observational study where 9 patients of non-African descent with 11 keloids were included auricular keloids that were characterized by asymptomatic sessile, firm, disfiguring nodules involving the ears, originated due to ear piercing, boil, or any skin disease. The current study covered the period from January 2022 to March 2024 at the Department of Dermatology, Baghdad Teaching Hospital, Baghdad, Iraq. Informed consent was obtained from the two patients regarding the publication of their digital pictures. The study complied with principle of Helsinki in 1964 as well as its modification in October 2024. The current study was approved by the Ethical Approval Committee. The whole participants were meticulously learnt about the methodology, potential benefits and risks, and any probable early adverse events related to the study.

Irrespective of the disease duration, the individuals of both sexes, any age, different ear keloid sizes, and whether single or multiple, unilateral or bilateral were enrolled in the present study. While those with systemic diseases such as cardiac disease, bleeding tendencies, immunocompromised state, uncontrolled diabetes mellitus, and pregnant or lactating women were excluded from the study.

Full data regarding the demographic and clinical status were registered from the medical records of every participant. Photographic documentation was done preoperatively, postoperatively, and on each subsequent follow-up visit.

Technique of the procedure:

- All procedures were performed by the first author.
- Under complete aseptic caution, patients were put in a supine position with the affected ear visible and cleaned.
- Subsequently, started the intralesional injection of keloidal mass as well as its base with a combination of triamcinolone (20 mg in 0.5ml), (10mg in one ml) methotrexate and 1 ml 2% xylocaine.

- Then shaving with number 15 scalpel was carried out, and the mass was completely removed, depending on palpation and the remaining earlobe softness skin.
- Touch with diathermy needle was performed to stop bleeding, and a simple dressing with an elastic adhesive bandage was done. An oral acetaminophen as a pain killer was prescribed for a few days.
- Thereafter, patients were seen after 3-4 weeks, and the same combination of injection at the base of the lesion was done, to be seen again after one month.
- Follow-up was carried out on a regular basis of 12 months to assess for any side effects and recurrence.

The whole participants were meticulously learnt about the methodology, potential benefits and risks, and any probable early adverse events related to the treatment method. The patient questionnaire reported the surgical effectiveness, acceptability of debulking, follow-up, and patient satisfaction (very satisfied, satisfied, and dissatisfied with the treatment). Scar perfection and progression of any complications were also reported.

Clinical evaluations were made using the modified form (By the authors) of the VSS (9), which included patient satisfaction, pliability, and lesion height (a total score of 8), at every visit and then at 12 months (**Table 1**).

Data were entered and analyzed using SPSS (Statistical Package for the Social Sciences) version 29

**Table 1** The modified-Vancouver Scar Scale (M-VSS).

Variable	Scar characteristics	Score
Patient (disfigurement) satisfaction	Very satisfied	0
	Satisfied	1
	Dissatisfied	2
Pliability (Hardness)	Normal (Soft)	0
	Supple (Partially soft)	1
	Yielding (Rubbery)	2
	Firm	3
Height	Normal (flat)	0
	<2 mm	1
	2 mm–5 mm	2
	>5 mm	3
Total		8

Maximum improvement = 0-1; Moderate = 2-3; Mild = 4-5; No response = 6-8

(IBM Corp. Released 2022. Armonk, NY, USA). The variables were presented as frequencies and percentages, besides, the mean and standard deviation. An independent t-test was used to compare the mean score of the Modified VSS score pre- and post-treatment. A P-value of less than 0.05 was considered as a statistically significant difference.

## Results

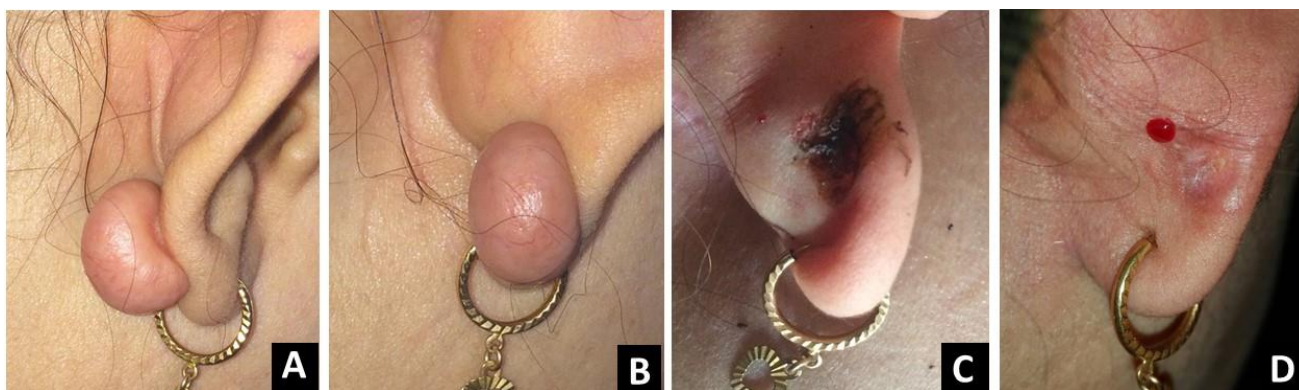
The study included 9 women with 11 keloids. Their ages ranged from 18 to 33 years with a mean  $\pm$  SD of  $27 \pm 7.2$  years (**Table 2**).

The duration of disease ranged from 6 to 24 months with a mean of 14 months. The participants included in this research belonged to the middle of Iraq and no one with African descent. All patients gave a history of ear

**Table 2** The demographic and clinical characteristics of the 9 patients with 11 keloids.

Variables	Values
Age	27(18-33) years
Disease duration	14(6-24) months
The longer diameter	1.3(0.3-2.5) cm
Distribution of the keloids lesion	
Unilateral (right ear)	5(55.5%) patients
Unilateral (left ear)	2(22.2%) patients
Bilateral	2(22.2%) patients
Location of keloid	
Earlobe	9(81.8%) lesions
Helix	2(18.2%) lesions
Anterior	8(72.7%) lesions
Posterior	3(27.3%) lesions
Side effects	
Pruritus	5(45.5%) patients
Mild tenderness	2(18.2%)
Clinical treatment assessment	
M-VSS after 1st month	
Maximum improvement	7(63.6%)
Moderate improvement	4(36.4%)
Mild improvement	1(9.1%)
No response	0(0%)
M-VSS after 1st year	
Maximum improvement	9(81.8%)
Moderate improvement	2(18.2%)
Mild improvement	0(0%)
No response	0(0%)

M-VSS = Modified-Vancouver Scar Scale



**Figure 1:** A 30-year-old female with auricular keloid at first visit (A and B), during the time of debulking and the intralesional injection of steroid and methotrexate (C), the same patient after one month plus repeating local injection (D).

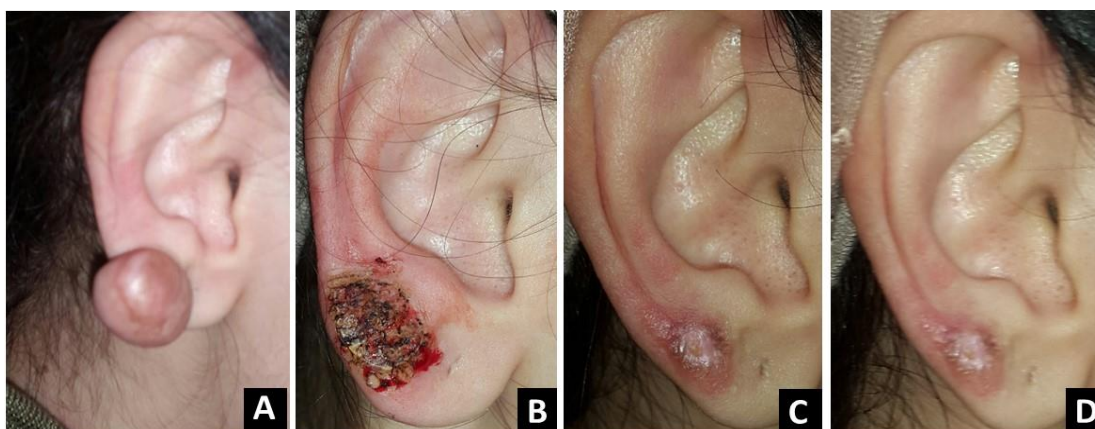piercing that was followed by the appearance of keloid, which almost involved the earlobes, and they had a negative family history. Seven (77.77%) patients had a single keloid on one side after ear piercing, while two (22.22%) patients had keloids on their two auricles. The diameter of the longest axis assessed by induration ranged from 0.3-2.5 cm, with a mean of 1.3 cm. Based on the location of auricular keloid, nine keloids (81.81%) were over the earlobe, and two (18.2%) were presented over the helix.

Nearly all participants tried different topical treatment but get no benefit. All patients had complete clearance of keloids without complications, like infection, recurrence, or new keloid formation, apart from tolerated mild tenderness and pruritus. The mean  $\pm$  SD of baseline M-VSS score was  $6.5 \pm 0.81$ . There was an

improvement in scores during follow-up examinations. The M-VSS score at the 1st year follow-up decreased for all patients to  $0.07 \pm 0.46$ , which was statistically significant ( $P$ -value=0.003). No relapses were recorded within the follow-up period. Almost all patients were satisfied with this treatment strategy (Figures 1 & 2).

### Discussion

Keloid scars are benign, but physically and cosmetically disturbing for patients, and challenging for doctors to treat. Moreover, they can impact patients' quality of life. There are numerous methods of treatment, ranging from non-surgical to surgical strategies, with different levels of response and recurrence rates.<sup>15</sup> Especially, in sessile-type keloids, highlights the need for modified therapy plans and



**Figure 2:** A 27-year-old woman with auricular keloid at first visit (A), during the time of debulking and the intralesional injection of steroid and methotrexate (B), after one month follow-up and repeating injection (C), the same patient after six months of follow-up (D).

additional research into targeted treatments. Currently, the shave excision, that concomitantly precede and follow by intralesional injection of steroid and methotrexate are obtaining approval for the management for ear keloids. The novel treatment in the present study carries promising cosmetic outcomes, no recurrence within a one-year follow-up, and minimal side effects.

Over 27 months, this study included 11 auricular keloids that were characterized by asymptomatic sessile, firm, disfiguring nodule involved the ears, resistant to different treatments, and they were a common sequelae of ear trauma (piercing). They share the same previously reported features, particularly these lesions are characterized by their extension beyond the original wound limits, and are notably prevalent and have been associated with higher recurrence rates post-treatment.<sup>16,17</sup>

The present study showed that auricular keloids predominantly affect non-African descent young women. They had a history of ear piercing that was followed by the appearance of the lesion. Previous reports found the mean age of patients with auricular keloids to be  $27.1 \pm 7.5$  years, ranging from 18 to 55 years.<sup>17,18</sup> These findings align with larger epidemiological data, that keloid development is most prevalent between the ages of 11 and 30.<sup>17</sup> The higher occurrence in this age group females may be related to our community's frequent exposure to hazard factors (ear piercing) as a sign of beauty, which is the main cause leading to keloid development, particularly in women than in men. Understanding the age distribution of ear keloids is critical for evolving prevention and treatment modalities.

The present clinical observation reported undetectable family tendency, and could be attributed to the small number of cases in this work. Besides, it suggested that auricular keloids often developed within months to years following the initial ear-piercing skin injury. Recently, published studies have provided insights into the duration and familial tendency of auricular keloids.

A prospective observational study involving 50 patients with ear keloids reported a mean age of  $27.1 \pm 7.5$  years, with the duration of disease ranging from 19 to 180 months post-piercing or healed furuncle, indicating a prolonged disease course in many cases.<sup>19</sup> Moreover, the familial predisposition in a study analyzing 259 participants found that 19.3% had a positive family history of keloids.<sup>20</sup>

The current research provided insights into the common regions and sizes of ear keloids, and identified that 77.77% of patients had a single keloid on one side after both ears piercing. The question to be raised why ear keloids are more frequent in one side of ears? Well, it is difficult to have full answer but we can speculate that either the piercing is more traumatic or the associated infection in the affected site. Moreover, the auricular keloid mainly involved the earlobe and the helix in 81.81%, and 27.27% of cases, respectively. The mean diameter of the longest axis was 1.3 cm. These findings are comparable with preceding research, which reported similarly, the ear lobule and helix as common sites for keloid formation, predominantly following ear piercing.<sup>21</sup> Recent scientific studies found that the ear lobule was the most frequently affected site, accounting for half of the cases, followed by the helix and the retro-auricular area, while the keloid sizes varied from 0.5 to 3.5 cm in diameter.<sup>18,19</sup> These data underline the prevalence of keloid formation in specific locations of the ear, particularly the lobule and helix, and underscore the variability in keloid sizes among affected subjects.

Although different topical treatment trials have shown nothing satisfactory, still many comparative reports have revealed promising outcomes. Since complete clearance is rarely achieved with monotherapy, we observed significant improvements in patient satisfaction, keloid size, as well as the M-VSS scores in this study. The findings consistently demonstrated the strong efficacy of intralesional injection of a combination of steroid and methotrexate. followed by surgical shaving, in treating auricular keloids. No relapses were recorded within a one-year follow-up

period. A study by Sharquie et al. assessed the efficacy of intralesional triamcinolone and methotrexate, both with and without surgical debulking, in treating body keloids. The results showed that this combination remedy led to significant improvement in keloid appearances, while the debulking group displayed superior outcomes.<sup>1</sup>

Furthermore, a previous comparative study evaluated the outcomes of intralesional methotrexate versus triamcinolone in treating keloids and hypertrophic scars. Their data found that both drugs were effective, but triamcinolone showed slightly better outcomes than methotrexate in terms of scar flattening and pigmentation normalization.<sup>22</sup> These recent facts highlighted the challenges in achieving complete clearance and preventing recurrence of auricular keloids. A shave excision then intralesional steroid and botulinum toxin A injections had previously tried with a promising option for treatment for pinna keloids.<sup>11</sup> moreover, adding the radiotherapy to tunnel shaped excision and botulinum toxin A injection achieved no recurrence of auricular keloids.<sup>23</sup> Another published report including 8 patients, showed that the combination of keloid excision and 5-aminolevulinic acid photodynamic therapy (ALA-PDT) was an effective and well-tolerated treatment for auricular keloids, without postoperative recurrence. Suggesting that the surgery, plus ALA-PDT targets abolished fibroblasts within the wound base.<sup>24</sup> In a most recent (2025) study, revealed that patients treated with intralesional injections of triamcinolone combined with hyaluronidase showed an encouraged resolution for managing auricular keloids. But about 22% had recurrence within the follow-up period.<sup>19</sup> These findings underscore the importance of individualized, multimodal therapy plans and close monitoring to optimize results and reduce the high risk of recurrence in auricular keloids.

## Conclusion

Intralesional methotrexate injection plus triamcinolone

combined with shaving strongly offers an effective and innovative treatment modality for auricular keloids. The combination appears to prevent recurrence and subsequent scar formation. Further research with higher sample sizes and extended follow-up periods is necessary to confirm long-term safety and efficacy.

## References

1. Sharquie K, Noaimi A, Al-Karhi M. Debulking of keloid combined with intralesional injection of methotrexate and triamcinolone versus intralesional injection of methotrexate and triamcinolone. *J Clin Dermatol Ther.* 2014;**1(3)**:8-21.
2. Gauglitz G, Kunte C. Recommendations for the prevention and therapy of hypertrophic scars and keloids. *Der Hautarzt.* 2011;**62**:337-46.
3. Kim H-D, Hwang S-M, Lim K-R, Jung Y-H, Ahn S-M, Song JK. Recurrent auricular keloids during pregnancy. *Arch Plast Surg.* 2013;**40(01)**:70-2.
4. Donkor P. Head and neck keloid: treatment by core excision and delayed intralesional injection of steroid. *J Oral Maxillofac Surg.* 2007;**65(7)**:1292-6.
5. Domenico P, Giuliana C, Daniele B, Bruno B, Alessandro G, Fabrizio M, et al. Ear keloids: An innovative 3-steps combined treatment. *Skin Res Techn.* 2023;**29(11)**:e13506.
6. Al-Ani RM, Kubaisi TA. Unilateral auricular multiple trichoepitheliomas: a case report and review of literature. *Egyptian J Otolaryngol.* 2023;**39(1)**:63.
7. Chuangsuwanich A, Gunjittisomrarn S. The efficacy of 5% imiquimod cream in the prevention of recurrence of excised keloids. *Journal-Medical Association Of Thailand.* 2007;**90(7)**:1363.
8. Berman B, Perez OA, Konda S, Kohut BE, Viera MH, Delgado S, et al. A review of the biologic effects, clinical efficacy, and safety of silicone elastomer sheeting for hypertrophic and keloid scar treatment and management. *Dermatol Surg.* 2007;**33(11)**:1291-303.
9. Sullivan T, Smith J, Kermod J, McIver E, Courtemanche D. Rating the burn scar. *J Burn Care Rehabil.* 1990;**11(3)**:256-60.

10. Yıldız E. Triple treatment in ear keloids: Comparison of post-excisional intralesional steroid and platelet-rich plasma treatment. *Am J Otolaryngol*. 2021;**42**(3):102935.
11. Tran JV, Lultschik SD, Ho JS, Sapra S, Dong K, Gusic K. Concomitant therapy of surgical shave excision and intralesional injections for ear keloids: Early results from a retrospective cohort study. *Scars Burns Heal*. 2022;**8**:20595131221098531.
12. Li H, Song T. 3d printed custom made pressure clips for ear keloid treatment after surgical excision. *Am J Otolaryngol*. 2020;**41**(4):102516.
13. Han X-M, Jiang S-Q, Hu C-X, Du M, Zhao L. Triple Surgical Technique for the Repair of Auricular Keloids: Achieving Perfect Restoration of the Ear Contour. *Aesthet Plast Surg*. 2024:1-9.
14. Mane BS, Gavali RM. Our Experience at Tertiary Medical College—Intralesional Injection of Triamcinolone Acetonide Versus Injection Verapamil Following Keloidectomy with Fillet Flap in Auricular Keloids. *Indian J Otolaryngol Head Neck Surg*. 2024;**76**(1):237-44.
15. Ogawa R. The most current algorithms for the treatment and prevention of hypertrophic scars and keloids. *Plast Reconst Surg*. 2010;**125**(2):557-68.
16. Park TH, Seo SW, Kim JK, Chang CH. Earlobe keloids: classification according to gross morphology determines proper surgical approach. *Dermatol Surg*. 2012;**38**(3):406-12.
17. Mohammadi AA, Kardeh S, Motazedian GR, Soheil S. Management of ear keloids using surgical excision combined with postoperative steroid injections. *World J Plast Surg*. 2019;**8**(3):338.
18. Hung Y-T, Lin S-M, Tzeng I-S, Ng CY. Optimizing surgical outcome of auricular keloid with a novel multimodal approach. *Scientific Rep*. 2022;**12**(1):3533.
19. Bangalore Narayanaswamy V, HM S, HN U, HK N. Intralesional steroid injection in keloid ear—a prospective observational study. *Egyptian J Otolaryngol*. 2025;**41**(1):4.
20. Shaheen A, Khaddam J, Kesh F. Risk factors of keloids in Syrians. *BMC Dermatol*. 2016;**16**:1-11.
21. Chaidas K, Fotiadis G, Katotomichelakis M. Large Bilateral Auricular Keloid Formation Secondary to Prolonged Facial Mask Use During COVID-19 Pandemic. *Ear Nose Throat J*. 2024:01455613241254159.
22. Viera MH, Amini S, Valins W, Berman B. Innovative therapies in the treatment of keloids and hypertrophic scars. *J Clin Aesthet Dermatol*. 2010;**3**(5):20.
23. Hou J, Liu C. The Combination of Tunnel Shaped Excision with Radiotherapy and Injection of Type A Botulinum Toxin in the Treatment of Auricular Keloids. *Aesthet Plast Surg*. 2025;**1**:1-7.
24. Lu Z, Zhu D, Yang Y, Kou H, Li X, Zhang J. Assessment of the efficacy and safety of auricular keloids excision followed by 5-aminolevulinic acid photodynamic therapy. *Photodiag Photodynamic Ther*. 2024;**50**:104335.